



PATIENT PRESENTING CLINICAL SIGNS

Rosy Gerlach Intermittent limping rear legs, Bilateral effusions, CCL injury RH

SPECIES

Canine

Abnormal PE/Chem/CBC/UA Results: Partial tear RH CCL, Meniscus good, Has a slight Cranial drawer and CTT worse in flexion

ULTRASONOGRAPHIC STUDY OF THE RIGHT STIFLE JOINT

ULTRASONOGRAPHIC FINDINGS

BREED

German Shepherd X

Moderate anechoic effusion, moderate synovial swelling and mild periarticular osteophytes are seen in the supra and infrapatellar recesses of the right stifle joint. The cranial cruciate ligament is thick with slightly ill-defined margins and echogenic foci indicating partial fiber disruption.

SEX

The medial and lateral meniscus are in situ, smoothly delineated and of uniform internal echoarchitecture. The patellar tendon presents within normal limits.

FS

ULTRASONOGRAPHIC DIAGNOSIS

AGE

- Partial rupture of the right cranial cruciate ligament with moderate osteoarthritis of the right stifle joint

3yr

INTERPRETATION OF FINDINGS & FURTHER RECOMMENDATIONS

INTERPRETED BY

Nele Eley (Ondreka),
DVM Dr. med. vet.,
DipECVDI

The imaging findings support the presence of partial cranial cruciate ligament tear in the right stifle with associated synovitis, effusion and degenerative joint changes. There is no evidence of meniscal tearing. Surgical management by means of TTA was performed and routine post-surgical management is recommended.

HOSPITAL NAME

Westview Veterinary
Hospital

REFERRING VET

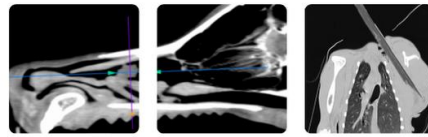
Dr Brian Barnes

INVOICE

23100

DATE

12/03/2025



PATIENT

Rosy Gerlach

SPECIES

Canine

BREED

German Shepherd X

SEX

FS

AGE

3yr

INTERPRETED BY

Nele Eley (Ondreka),
DVM Dr. med. vet.,
DipECVDI

HOSPITAL NAME

Westview Veterinary
Hospital

REFERRING VET

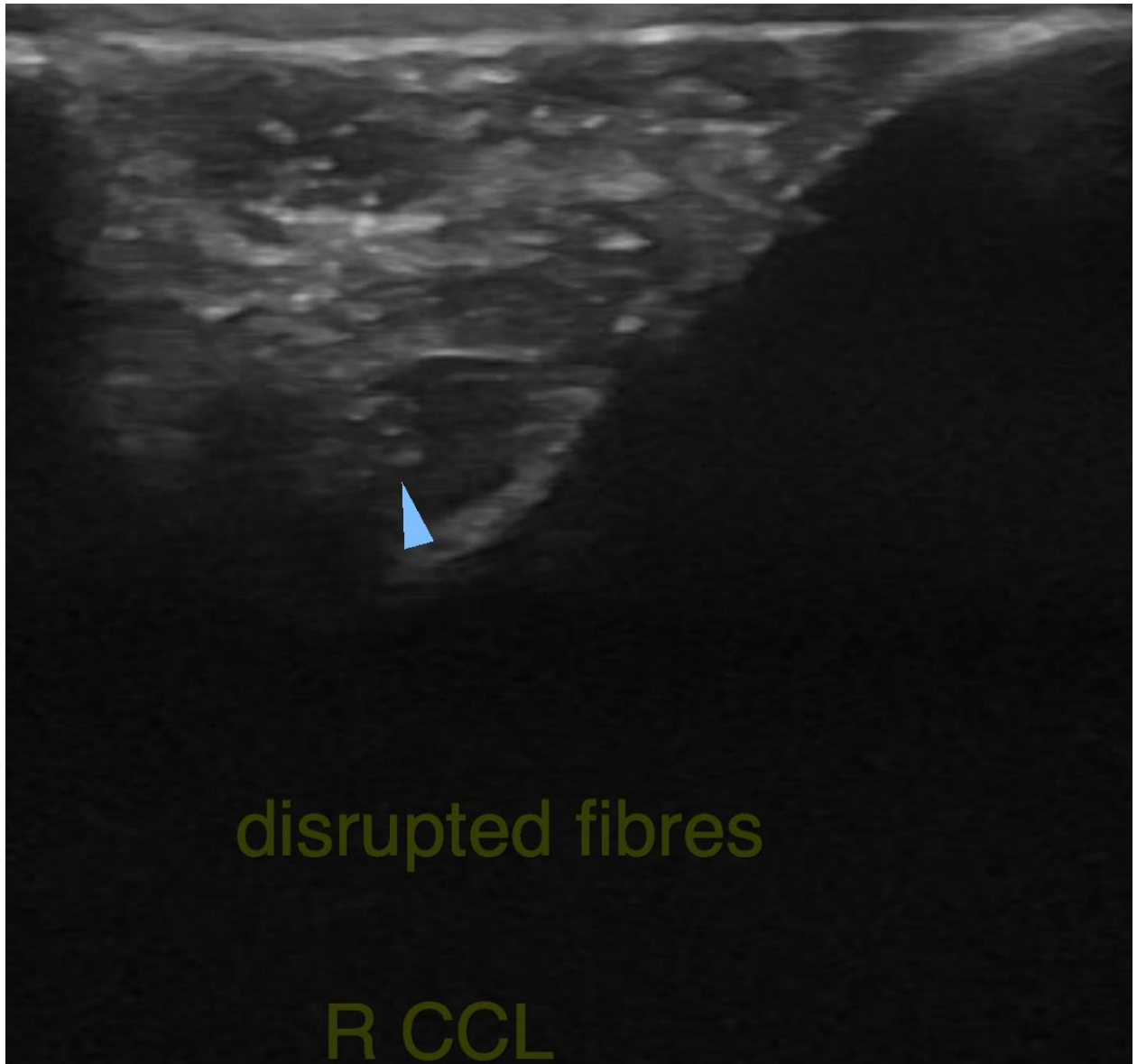
Dr Brian Barnes

INVOICE

23100

DATE

12/03/2025





PATIENT

Rosy Gerlach

SPECIES

Canine

BREED

German Shepherd X

SEX

FS

AGE

3yr

INTERPRETED BY

Nele Eley (Ondreka),
DVM Dr. med. vet.,
DipECVDI

HOSPITAL NAME

Westview Veterinary
Hospital

REFERRING VET

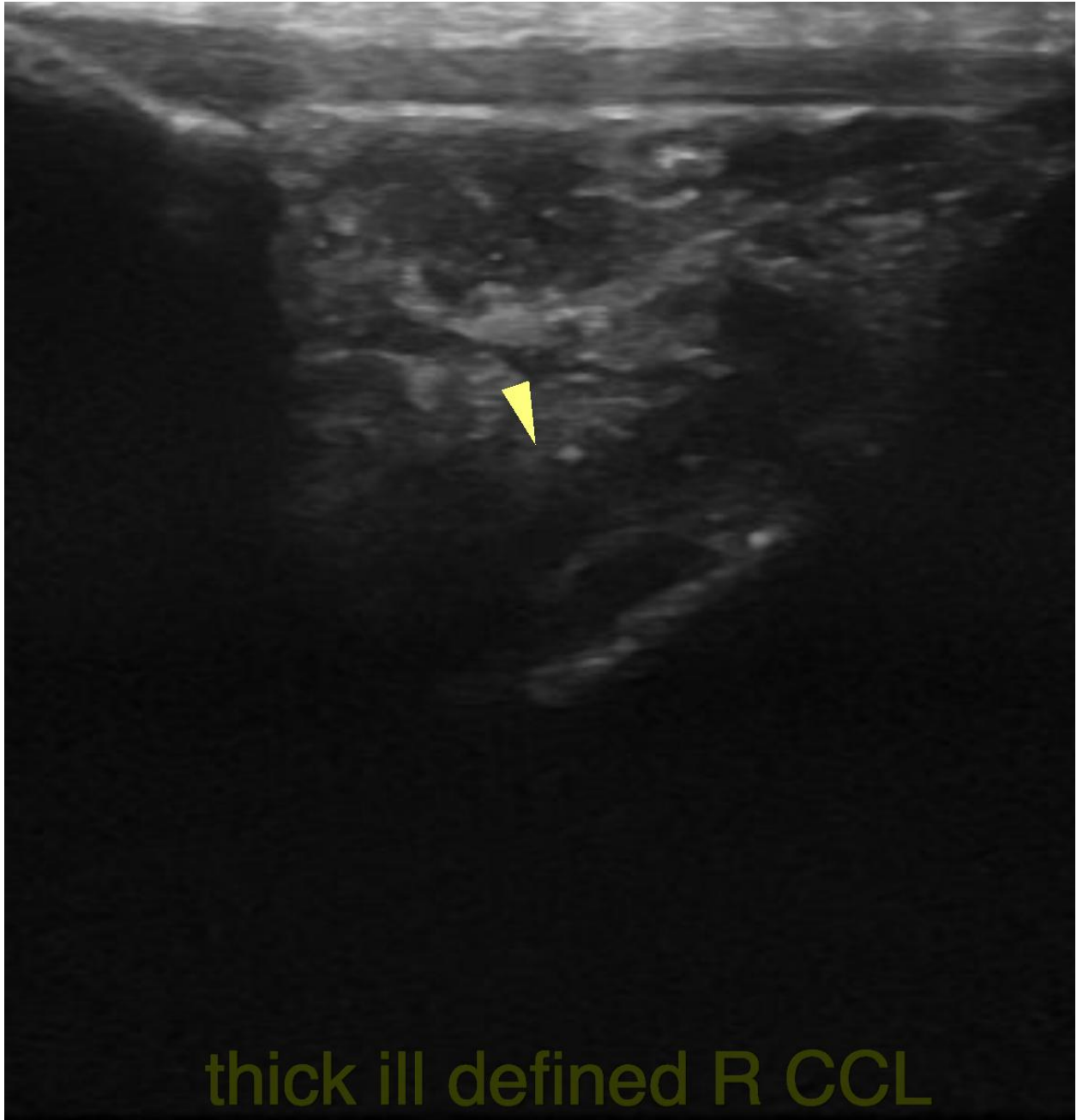
Dr Brian Barnes

INVOICE

23100

DATE

12/03/2025



thick ill defined R CCL



PATIENT

Rosy Gerlach

SPECIES

Canine

BREED

German Shepherd X

SEX

FS

AGE

3yr

INTERPRETED BY

Nele Eley (Ondreka),
DVM Dr. med. vet.,
DipECVDI

HOSPITAL NAME

Westview Veterinary
Hospital

REFERRING VET

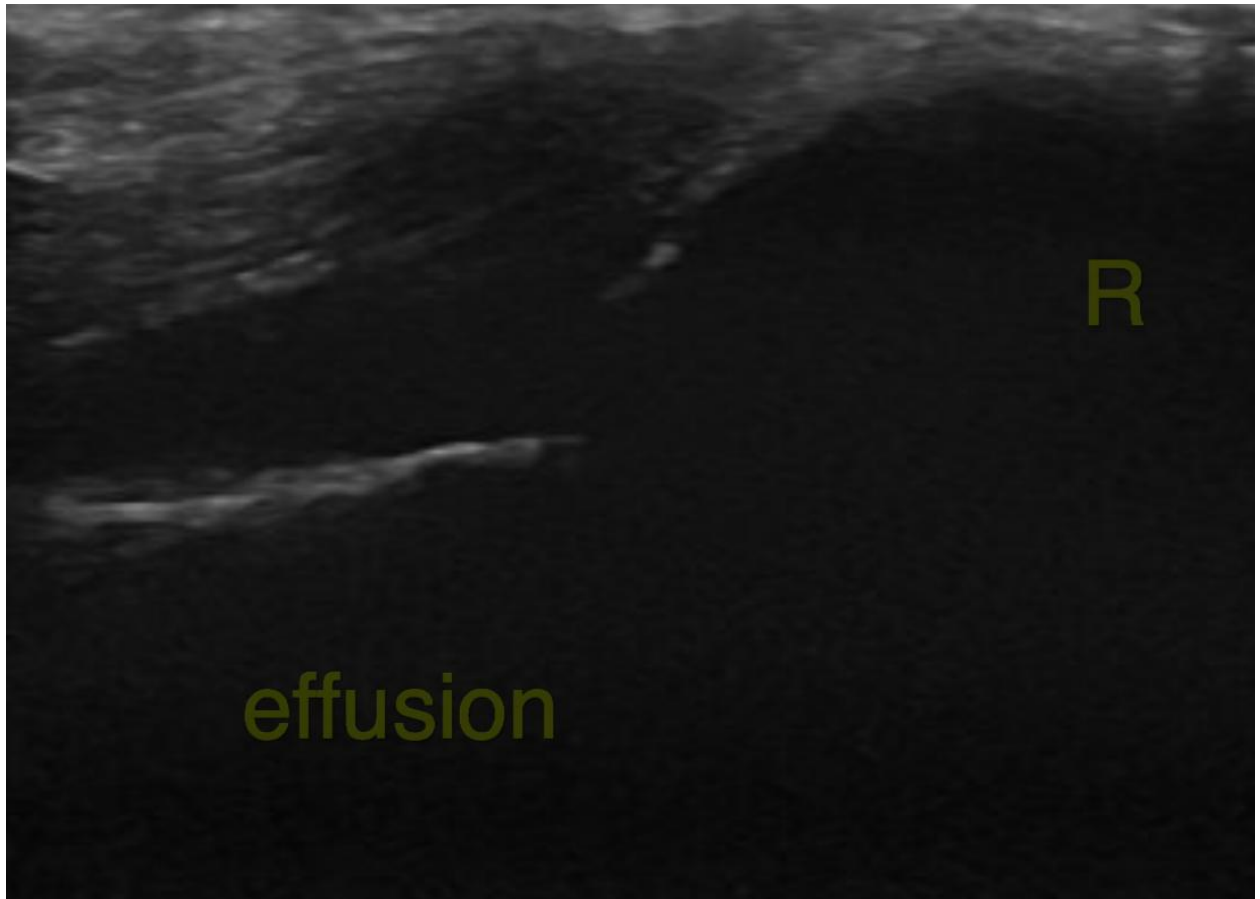
Dr Brian Barnes

INVOICE

23100

DATE

12/03/2025





PATIENT

Rosy Gerlach **The information and recommendations provided are based on the images presented by the referring veterinarian. No evaluation can be communicated regarding pathology that was not visible in the image/video clips provided.**

SPECIES

Canine Thank you for this referral. If the clinical or image interpretation does not parallel your findings or if I can be of any further assistance please contact me.

BREED

German Shepherd X **Nele Eley (Ondreka), DVM, Dr. med. vet., DipECVDI**
European Specialist in Veterinary Diagnostic Imaging, Cert. Radiology,
Senior lecturer University of Giessen/Germany, Veterinary Faculty, Department of Radiology.
info@sonopath.com

SEX

FS

AGE

3yr

INTERPRETED BY

Nele Eley (Ondreka),
DVM Dr. med. vet.,
DipECVDI

HOSPITAL NAME

Westview Veterinary
Hospital

REFERRING VET

Dr Brian Barnes

INVOICE

23100

DATE

12/03/2025